

The cover of the European Musculoskeletal Review 2007, Issue 2. It features a brown background with a faint, stylized globe graphic. The title "EUROPEAN MUSCULOSKELETAL REVIEW 2007" is in large, bold, white and black letters. "Issue 2" is in smaller black letters at the bottom right of the cover.

EUROPEAN MUSCULOSKELETAL REVIEW 2007

Issue 2

EXTRACT

Transforaminal Endoscopic
Surgery – Technique and
Provisional Results in
Primary Disc Herniation

a report by

Menno Ipreburg

Orthopaedic Surgeon, Spine Clinic
Ipreburg, Heerenveen

Transforaminal Endoscopic Surgery – Technique and Provisional Results in Primary Disc Herniation

a report by

Menno Ipreburg

Orthopaedic Surgeon, Spine Clinic Ipreburg, Heerenveen

Back pain with or without sciatic symptoms (leg pain) is very common, with a lifetime prevalence in western industrialised countries of up to 80%.¹ In 5% of patients with acute lumbago, symptoms are thought to be caused by lumbar disc herniation.² Lately, both medical experts and patients have shown a growing interest in minimally invasive spine surgery. This kind of procedure has proved to be a reliable treatment for several spinal disorders. In the 1970s, Kambin^{3,4} and Hijikata⁵ began to use specially designed cannulas to perform percutaneous dorsolateral nucleotomy, with a reported satisfactory outcome in 75%

Lately, both medical experts and patients have shown a growing interest in minimally invasive spine surgery.

of their patients. More recently, Anthony Yeung,⁶ Martin Knight,⁷ San Ho Lee^{8,9} and Thomas Hoogland,^{10–12} as well as others,^{13–18} have used more laterally located entrance points with the help of smaller-calibre rod lens fibre optics. The procedure described below was developed by Dr Thomas Hoogland in conjunction with JoiMax in Germany. I have been using it since August 2004, and in the last three years I have used the procedure in 330 cases. Below I will describe the technique and provide a short resumé of the preliminary results of a survey of the first 176 cases of primary disc herniations.

Operating Technique

Positioning the patient well is essential. It must be possible, with the help of the image intensifier, to view the spine closely in two directions – anteroposterior (AP) and lateral – at an angle of 90° exactly. My personal preference, after approximately 300 patients, is the lateral position. Confirmation of the position of the annular tear, protrusion and/or sequestered disc material can be obtained by intra-operative discography.

The patient lies on his or her left side. The position of the iliac crest is marked and a line is drawn across the processus spinosi (see *Figure 1*). Depending on the patient's posture, a line is drawn 14–15cm from the centre if the herniation is at the level L5–S1; with herniations at levels L4–5 and L3–4, the distance is reduced by 1 or 2cm, respectively. Local anaesthesia is administered at the place of entrance (see *Figure 2*). The needle is set and its position is checked by means of the image intensifier (see *Figure 3*). After the needle has reached the correct

position – the place where the hernia is most prominent – a guidewire is inserted (see *Figures 4* and *5*). Next, the first conical rod is introduced over the guidewire and, subsequently, the first, second and third conical tubes, in order to stretch the soft parts. The second and third conical tubes are then removed and the first reamer is introduced, in an anti-clockwise direction.

Using the image intensifier to check the procedure, a fraise is inserted to a minimum of 1mm medially from the medial interpedicular line, then the fraise, the first conical tube and the first conical rod are removed. However, the guidewire remains in place at this point. For the patient, this first fraise is often the most painful. At levels L5–S1, the procedure is usually carried out close to the iliac crest. It may be painful if the iliac crest is passed, so it is recommended that the iliac crest receive extra local anaesthetic. A second conical rod is inserted over the guidewire up to the required level; this is checked using the image intensifier, then the second conical tube and the second fraise are inserted. The process is repeated for the third conical rod, tube and fraise. In cases of L4–5 and L5–S1 herniations, the patient is told to inform the operating team if he or she experiences pain under the knee. Sometimes, pain is felt in the trochanter major region during fraising, or even radiating pain in the proximal lateral upper leg. However, the patient is usually comfortable and can have a conversation with the anaesthetist during the operation (vocal anaesthesia).

The working cannula can be introduced over the third conical rod. Its tip should be located on the hernia. To achieve sufficient depth, it is often necessary to use the hammer for the last stage, after removing the guidewire and the third conical rod (see *Figure 6*). The image intensifier continuously checks the position of the working cannula (see *Figure 7*).

Next, the foraminoscope is introduced and the hernia removed.

Menno Ipreburg runs a Spine Clinic at the Abe Lenstra Football Stadium in Heerenveen, The Netherlands, where he performs mainly transforaminal endoscopic surgery/disectomy in day surgery under local anaesthesia. Prior to this, he worked in the Orthopaedic Department of the Wilhelmina Hospital in Assen, The Netherlands, where from 1997 onwards he developed the Joint Care Programme for total hip and knee replacements; in 2002 and 2003, the department was chosen as the best in The Netherlands by Elsevier Magazine. Dr Ipreburg was a founding member of the Dutch Arthroscopy Society and has twice been an invited speaker at the Annual Meeting of the Dutch Orthopaedic Society (NOV): once on the topic of lumbar microscopic disectomy (1997), and once on endoscopic carpal tunnel release (2003). After graduating in medicine and pursuing additional training in surgery and gynaecology, Dr Ipreburg worked in Tanzania for three years, before completing post-graduate training in in orthopaedic surgery in Bonn.

E: info@rugkliniek-ipreburg.nl

Figure 1: Marking the Iliac Crest and Drawing a Line Across the Processi Spinosi

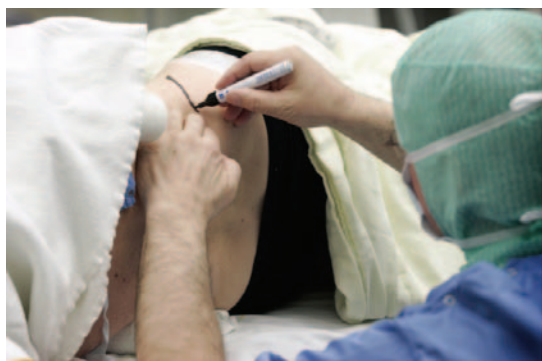
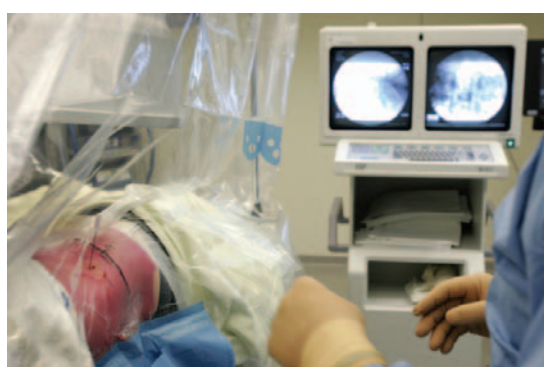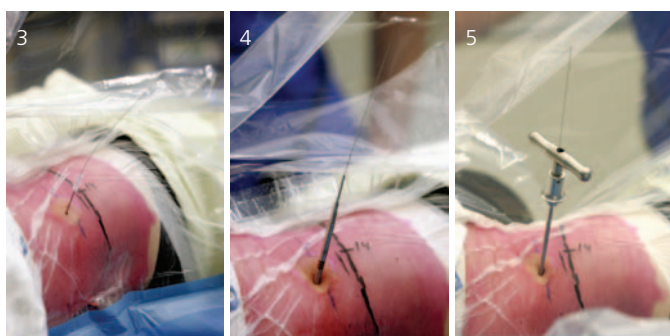


Figure 2: Administering Local Anaesthesia



Figures 3–5: Setting the Needle and Checking Its Position (3); Inserting the Guidewire (4 and 5)



Sometimes, a big sequester can be wholly removed immediately, but in most cases the 'crabmeat' has to be taken out with a small pair of tongs; this requires a lot of patience. Intra-operatively, the patient can be asked to move his or her leg.

After the hernia is removed, the working cannula is also removed and the skin is closed with an intra-cutaneously dissolving stitch. The patient usually leaves the clinic two hours after the operation. Our check-ups consist of a telephone call on the first post-operative day and another after two weeks, at which point physiotherapy is started. A final consultation takes place in the clinic after approximately six weeks.

Results

Between August 2004 and August 2007, in the Wilhelmina Hospital in Assen, The Netherlands and, after 1 January 2007, exclusively in the

Figure 6: Removing the Guidewire and the Conical Rod

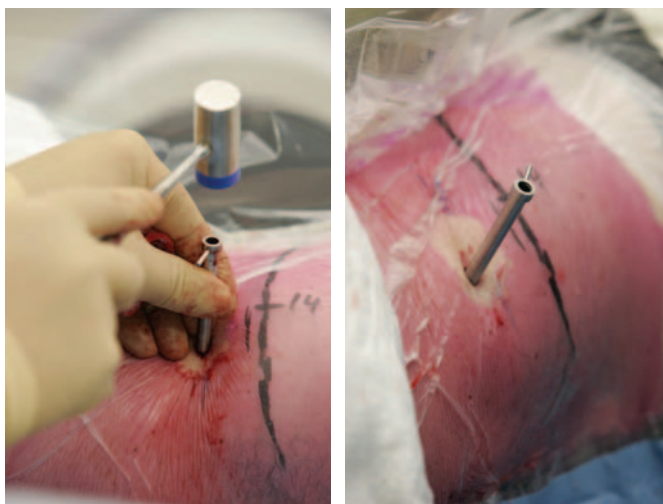
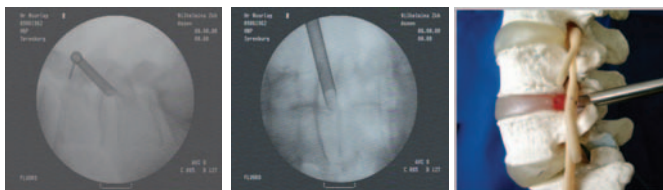

Figure 7: The Image Intensifier Continuously Checks the Position of the Working Cannula



Spine Clinic Ipreburg in Heerenveen, The Netherlands, 330 patients were operated on using this procedure.

Most of these patients had a primary herniation and some had foraminal stenosis; some of the latter group also had a foraminal herniation. We performed retrospective research on the first 176 operated patients: 73 females and 103 males, with an average age of 45 ± 4 years (range: 17–83). Contraindications for this procedure are dorsally dislocated disc herniation, central stenosis and tumours.

To get a impression of the results, we compared our results after transforaminal endoscopic surgery (TES) with results from the Swedish National Spine Register of patients who had undergone microscopic surgery.¹⁹ Of course, randomised controlled trials are needed, but these are impossible in a private facility such as the Spine Clinic Ipreburg as patients select such a facility for the specific purpose of being operated on endoscopically under local anaesthesia in day surgery. Therefore, we are setting up Web-based research for all of our operated patients within the parameters of the Swedish National Spine Register.¹⁹

The locations of the hernias (n=176) were as follows:

- L3–L4 – 8;
- L4–L5 – 63;
- L5–S1 – 78;
- recurrent L4–L5 – 9;
- recurrent L5–S1 – 6;
- hernia nuclei pulposi (HNP) with foraminal stenosis – 7; and
- foraminal stenosis – 5.

Figure 8: Visual Analogue Scale – Dutch Endoscopic Surgery versus Swedish Microscopic Surgery

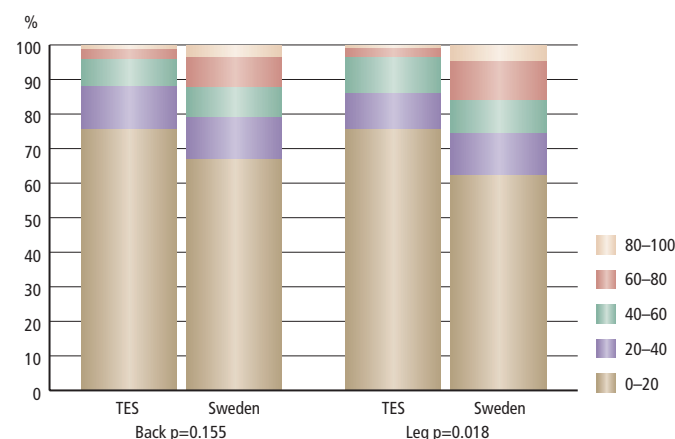
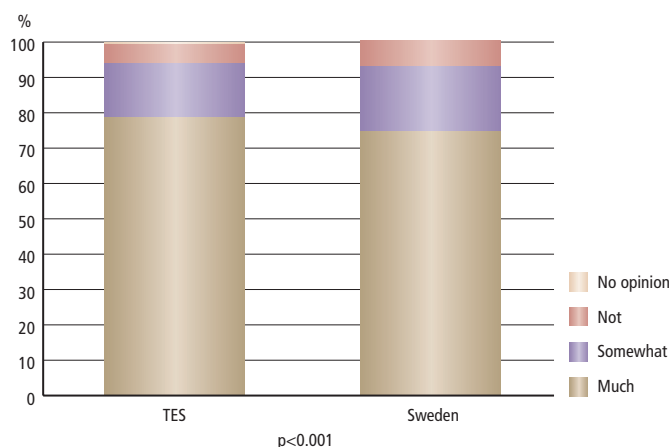


Figure 9: Satisfaction – Dutch Endoscopic Surgery versus Swedish Microscopic Surgery

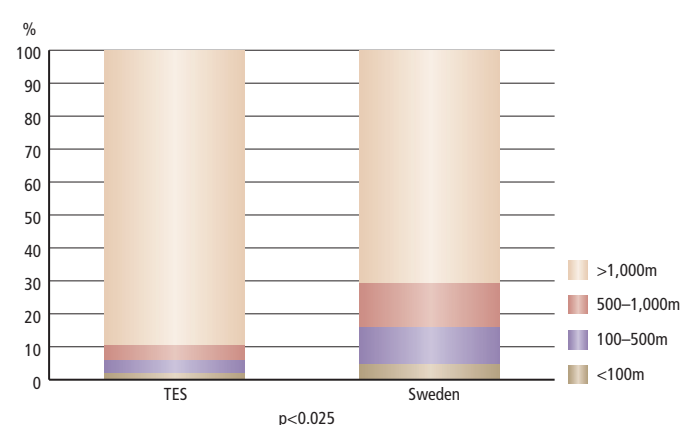


From these patients, those with a first disc herniation (n=149) were picked. In this group there were 62 females and 87 males. Average age was 43 ± 12 years (range: 17–82). Visual Analogue Scale (VAS) scores for the back and the leg and Roland and Oswestry scores were sent to all patients, and we received a reply from 106 (71%).

Conclusions

Although these results are preliminary and further studies are needed, we conclude that we achieved good clinical results with TES under

Figure 10: Walking – Dutch Endoscopic Surgery versus Swedish Microscopic Surgery



local anaesthesia on an outpatient basis. Our patients were highly satisfied, and in most parameters we saw better results than the Swedish registry data (see *Figures 8–10*). Our recurrence rate was 6%. As with every surgical intervention, the right diagnosis is essential in order to achieve good results. Currently, patients with a hernia at the level L4–5 are doing better than those with a hernia at the level L5–S1. Most likely, the results for hernias at levels L5–S1 will improve in time as we gain experience. At the L5–S1 level, we now have to ream twice or even three times in order to reach the medially located hernia.

The advantages of TES are:

- only local anaesthesia;
- reduced risk of infection;
- reduced risk of instability;
- fewer subsequent scars;
- keyhole surgery; and
- short rehabilitation time.


The disadvantages of TES are:

- the long learning curve;
- only 2D view; and
- the need for new technology at a higher cost. ■

- Raspe H, Kohlman T, Die aktuelle Ruckenschmerzepidemie. *Therapeutische Umschau*, 1994;51(6):S367–74.
- Becker A, Chenot JF, Niebling W, Kochen MM, Leitlinie 'Kreuzschmerzen' Evidenz-basierte Leitlinie der Deutschen Gesellschaft fur Allgemeinmedizin und Familienmedizin, 2003.
- Kambin P, Arthroscopic microdiscectomy: lumbar and thoracic. In: White AH, Schoffernann JA (eds), *Spine Care St. Louis*, Mosby, 1995;Vol. 2:1002–16.
- Kambin P, Gellman H, Percutaneous lateral discectomy of lumbar spine, a preliminary report, *Clin Orthop*, 1983;174: 127–32.
- Hijikata S, Yamagishi M, Nakayama T, et al., Percutaneous nucleotomy. A new treatment method for lumbar disc herniation, *J Toden Hosp*, 1975;5:5–13.
- Yeung A, Tsou P, Posterolateral endoscopic excision for lumbar disc herniation, *Spine*, 2001;27(7):722–31.
- Knight M, et al. (eds), Endoscopic Laser Foraminoplasty. A two year follow-up of a prospective study on 200 consecutive patients. In: Gunzberg, Spalski (eds), *Lumbar Spinal Stenosis*, Lippincott, Williams & Wilkins, 1999;244–54.
- Ahn Y, Lee SH, Park WM, et al., Posterolateral percutaneous endoscopic lumbar foraminotomy for L5-S1 foraminal or lateral exit zone stenosis. Technical note, *J Neurosurg*, 2003;99 (Suppl. 3):320–23.
- Parke WW, Clinical anatomy of the lower lumbar spine. In: Kambin P (ed.), *Arthroscopic Microdiscectomy, Minimal Intervention in Spinal Surgery*, Baltimore, Urban & Schwarzenberg, 1991;11–29.
- Herniation, *Surgical Techniques in Orthopaedics and Traumatology*, 2003;55-120-C-40.
- Hoogland T, Percutaneous nucleotomy of thoracic discs, Programme Abstract at the 17th Annual Meeting of the International Intradiscal Therapy Society, Munich, 2004.
- Hoogland T, Godon T, Wagner C, Die endoskopische transforaminale Diskoplastik bei uberwiegend lumbalen Ruckenschmerzen, Programme Abstract at the 52. Jahrestagung der Vereinigung Sudddeutscher Orthopaden, Baden-Baden, 2004.
- Alfen FM, Endoscopic Transforaminal Nucleotomy (ETN), Programme Abstract at the 3rd Dubai Spine Conference, Dubai, 2005.
- Gibson A, Surgery for lumbar disc prolapse: Evidence from the 2004 Cochrane review, Programme Abstract at the 17th Annual Meeting of the International Intradiscal Therapy Society, Munich, 2004.
- Hellinger J, Technical aspects of the percutaneous cervical and lumbar laser-disc-decompression and laser-nucleotomy, *Neurol Res*, 1999;21:99–102.
- Krzok G, Early results after posterolateral endoscopic discectomy with thermal annuloplasty, Programme Abstract at the 17th Annual Meeting of the International Intradiscal Therapy Society, Munich, 2004.
- Levinkopf M, Caspi I, et al., Posterolateral Endoscopic Discectomy, Programme Abstract at the 18th Annual Meeting of the International Intradiscal Therapy Society, San Diego, 2005.
- Schubert M, Hoogland T, Endoscopic Transforaminal Nucleotomy with Foraminoplasty for Lumbar Disc Herniation, *Oper Orthop Traumatol*, 2005;17:641–61.
- Stromqvist B, Jonsson B, Fritzell P, et al., Results One-year Report of the Swedish National Spine Register, *Acta Orthopaedica*, 2005;76(Suppl. 319).

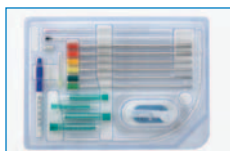
TESSYS™

Transforaminal Endoscopic Surgical System



- > Fragmentectomy
- > Foraminoplasty
- > Decompression
- > Nucleotomy
- > Annuloplasty
- > Discography

The TESSYS™ Procedure Kit System



TESSYS™ Disposable Access Kits



Color coded reamers in different specifications



TESSYS™ Instrument Set



Patented LOPS forceps system



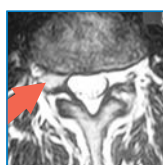
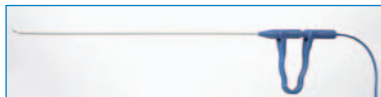
Color-coded instruments



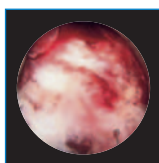
TESSYS™ Foraminoscopes



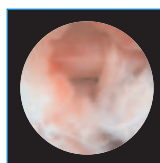
Surgi-Max™ Trigger-Flex™ RF-Probes



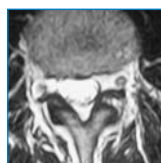Pre-surgical: L3-L4, lateral



Herniated fragment



Freed nerve root

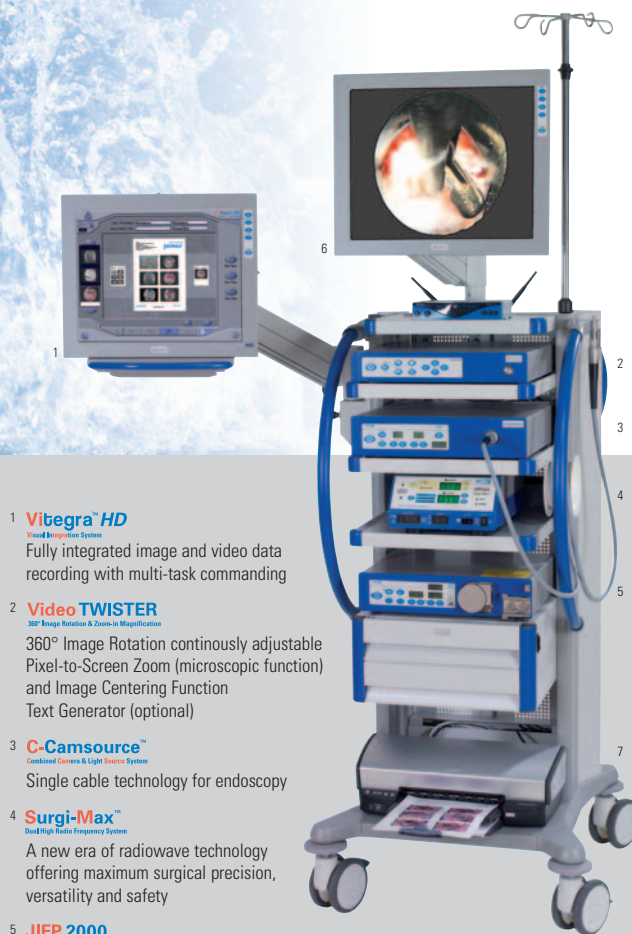

Post-surgical: L3-L4, lateral

medical solutions
joimax®

joimax Digital Endoscopy System

joimax provides the latest digital technologies for endoscopic surgery, specifically for performing the innovative, minimally invasive **TESSYS™** surgical spine procedure.



1 Vitegra™ HD

Visual Integration System

Fully integrated image and video data recording with multi-task commanding

2 Video TWISTER

360° Image Rotation & Zoom-In Magnification

360° Image Rotation continuously adjustable
Pixel-to-Screen Zoom (microscopic function)
and Image Centering Function
Text Generator (optional)

3 C-Camsource™

Combined Camera & Light Source System

Single cable technology for endoscopy

4 Surgi-Max™

Dual High Radio Frequency System

A new era of radiowave technology
offering maximum surgical precision,
versatility and safety

5 JIFP 2000

Wide-Range Irrigation Pump System

For arthroscopy and minimally invasive
spine surgery

6 JFM 1910

High Resolution Flat-screen Monitor

joimax Flatscreen Monitor

7 ICPP xxxx

joimax Photoprinter

Patents pending



0483

**joined minimal access
technologies**

joimax, Inc.

275 E. Hacienda Avenue
Campbell, CA 95008 USA

PHONE +1 408 370 3005

FAX +1 408 370 3015

MAIL usa@joimax.com

NET www.joimax.com

joimax GmbH

RaumFabrik 33a, Amalienbadstraße
76227 Karlsruhe - Germany

PHONE +49 (0) 721 255 14-0

FAX +49 (0) 721 255 14-920

MAIL info@joimax.com

NET www.joimax.com

WWW.TOUCHBRIEFINGS.COM



touch
BRIEFINGS

Cardinal Tower
12 Farringdon Road
London
EC1M 3NN

EDITORIAL
Tel: +44 (0) 20 7452 5133
Fax: +44 (0) 20 7452 5050

SALES
Tel: +44 (0) 20 7526 2347
Fax: +44 (0) 20 7452 5601

E-mail: info@touchbriefings.com
www.touchbriefings.com