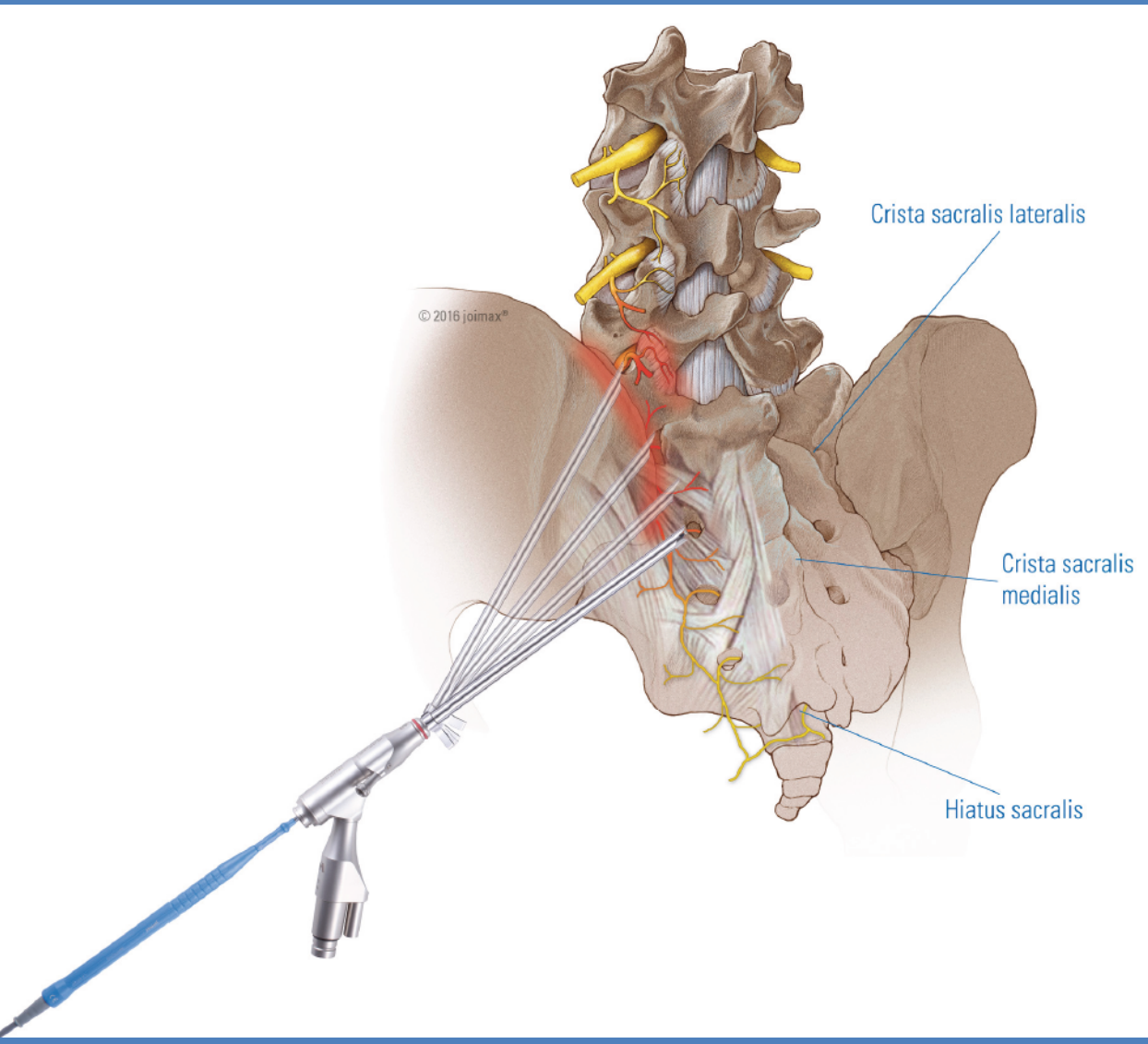


Endoscopic electrothermic (ESIJ) procedure of the sacroiliac joint

24-month follow up studies

R. Ibrahim, K. Gohlke, O. Decker
Dr. Decker Clinic / Pain Center, Munich, Germany



Introduction

Chronic low back pain (CLBP) that lasts for more than six months is estimated to occur in 60-80% of the general population in their lifetime and is associated with substantial healthcare costs. The sacroiliac joint (SIJ) complex is one of the major sources of chronic low back pain, accounting for around 10-33% of the total number of CLBP cases. The SIJ complex consists of the joint capsule, synovium, various muscles and ligamentous structures overlying the joint and neuronal structures that innervate the SIJ. Current interventional and surgical treatment options for SIJ pain perception complex include intraarticular or periaarticular injection, radio frequency ablation (RFA) and SIJ fusion. The described interventional procedures are simple procedures and provide quick pain relief, but the effect is short-lived. In addition, SIJ fusion is an invasive surgical procedure that should be reserved for refractory intractable pain of the SIJ. New endoscopic electrothermic procedures of the SIJ capsula, synovium, ligament and neuronal structures have been utilized in the treatment of facetogenic CLBP in a few number of clinical reports with favorable results, but to our knowledge, the efficacy of this technique when applied to SIJ-associated CLBP has not been reported. In this study, we utilized endoscopy for the precise microsurgical and ablation (ESIJ) of the potential pain generators associated with the SIJ and evaluated the clinical efficacy of this new technique.

Material and Methods

The institutional review board at our institution approved this study. The medical records of 30 consecutive patients who underwent ESIJ for SIJ arthropathy and pain in CLBP between January 2016 and February 2018 were reviewed. The inclusion criteria for this treatment were as follows:

- Patient with predominant back pain (CLBP) and signs and symptoms of SIJ involvement on physical examination and radiological tests (CT scan or MRI), unresponsive to conservative therapy including oral analgesics and physical or osteopathic therapy, persistent CLBP despite previous lumbosacral surgery or / and interventional pain treatment in 24 months follow up.

SIJ complex pathology as the main cause of CLBP is difficult to diagnose due to overlapping patterns with other sources of CLBP and varying patterns of pain between

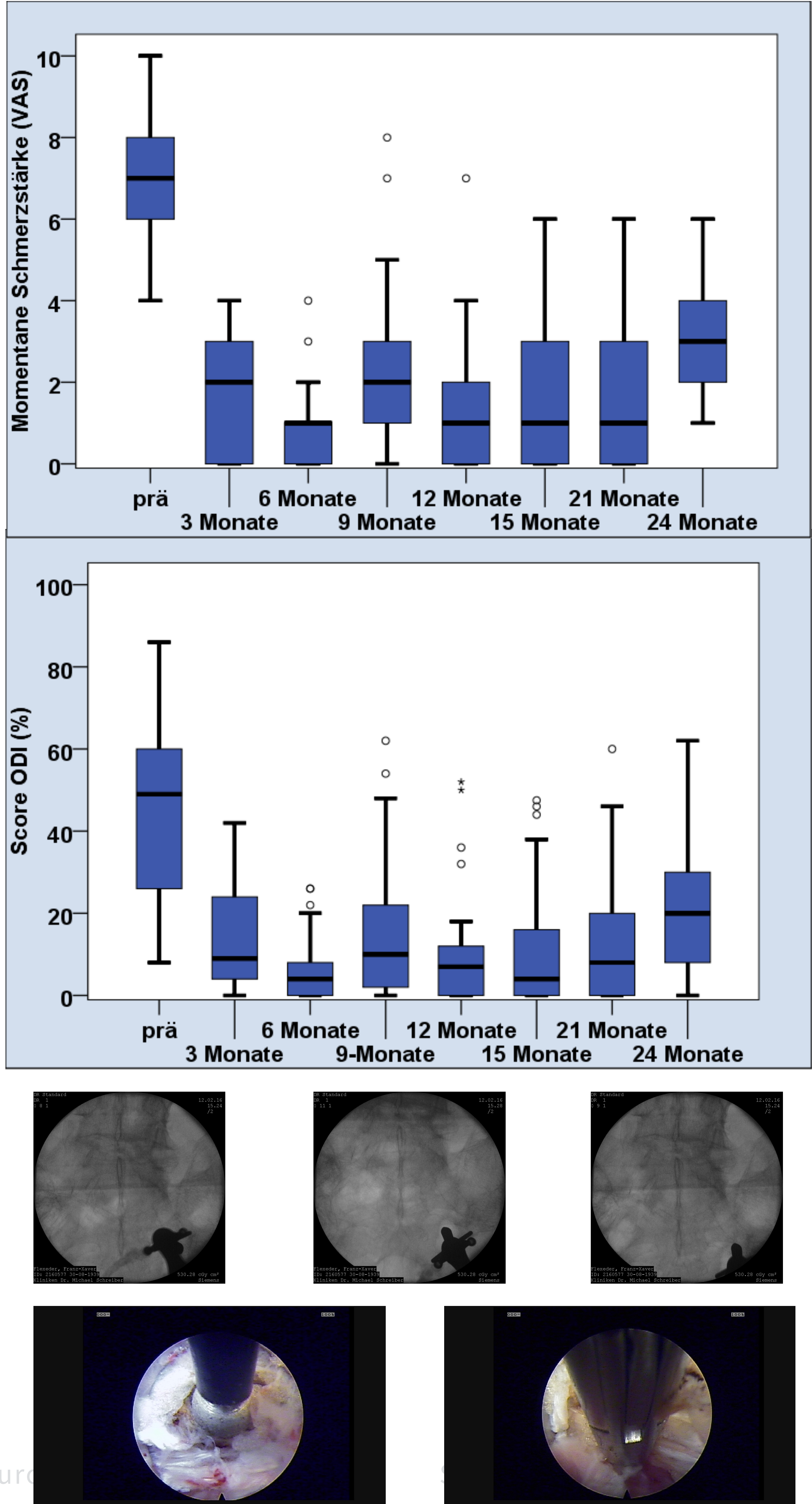
individuals. Radiographic findings of arthropathy or erosion of the SIJ, while not specific, may suggest SIJ based pathology in patients with clinical suspicion. While numerous physical examination methods have been suggested, provocative tests were reported to have more reliability in numerous reports. In order to confirm the SIJ pain as the main source of CLBP, three separate intraarticular SIJ and medial branch blocks of the lower facet joints (L4-S1) were performed under C-arm control at least 3 weeks before the ESIJ-procedure. If patient experienced 50% or higher improvement less than two weeks in pain from baseline according to visual analogue scale (VAS) after this block, SIJ complex was considered to be the main pain generator, and ESIJ was scheduled. Patient with blockades, irritation, tumors of the SIJ and nerve root neuropathy or rheumatic diseases or other severe comorbid diseases and medical conditions were excluded. All patients were followed for a minimum of 24 months after the procedure ESIJ in outpatient pain clinics. ESIJ was performed in the operating theatre room in full anaesthesia. Patients were discharged 3 days after the procedure. All patients were followed up at the outpatient clinic at 3, 6, 9, 12, 15 and 24 months after the procedure and annually thereafter by ODI and VAS scores.

Surgical Techniques

Under endoscopic visualisation, the posterior sacroiliac ligaments, capsule, synovium and its overlying soft tissue were prepared microsurgically and neuronal structures ablated (lateral branch) using a Trigger Flex mono- or bipolar probe that was introduced through the working channel of the endoscope. First, we released the soft tissue and the gluteal muscle to reach in depth the SIJ complex structures: Second, after visual confirmation of the long posterior sacroiliac ligament and the shining posterior capsule, we released and ablated them including perforating innervating branches in the cranial and lateral direction of S1 to S3 foramen (lateral branches - margins), in caudal and medial direction of L4 to S1 facet joint (medial branches - margins). We attempted to visually confirm the lateral branches exiting the sacral foramina and the branches coursing toward the SIJ when possible to ensure accurate nerve lesioning. Continuous saline irrigation was maintained throughout the procedure to minimize thermal injury to the surrounding structures. After ESIJ procedure of the target points S1 to S3 foramen (and L4 to S1 facet joints) the endoscope and cannula were removed.

Results and Conclusion

More than 350 endoscopic procedures of SIJ (ESIJ) were performed from January 2016 till February 2018. 30 patients with SIG arthropathy in CLBP over 6 months were included by precise criteria (s.e.). At baseline the VAS was 7,23, ODI 44,8 and age of 56 (11 male, 19 female). After the ESIJ procedure the patient had a significant improvement in pain relief (measured by VAS) and functional ability (measured by ODI) at 3 to 24 months: VAS reduction from 7,23 baseline to 1,72 / 2,82 after 21/24 months significantly by 80% pain relief ODI ability improvement from 44,8 baseline to 22.2 significantly in lumbar function.



This new easy to perform endoscopic electrothermic procedure of the SIJ (ESIJ) shows good to excellent results in SIJ arthropathy in relation to pain relief and functional capacity in long term analysis. Further research are needed to confirm these results.

References(1*):
Won-Suh Choi et al.: Endoscopic radio-frequency ablation of the SIJ.. Bio Med Research Int. Vol 2016 Article ID