

Developments in the Area of Endoscopic Spine Surgery

a report by

Florian Maria Alfen, Beate Lauerbach and Wolfgang Ries

Orthopaedic Surgeon, Private Practice, Würzburg

Pioneers in Endoscopic Spine Surgery

Minimally invasive spinal surgery is emerging as an alternative, reliable method of treatment for a variety of spinal disorders. The operative techniques being used for discectomy, retrieval of herniated disc fragments and stabilisation of unstable spinal motion segments are being utilised more widely on a daily basis.¹ Mixer, Barr and Dandy are credited with the diagnosis and treatment of herniated lumbar discs via laminectomy and the exposure of the spinal canal.^{2,3} Within the last 40 years many investigators have attempted to find alternatives to laminectomy and discectomy, including evacuation of the nucleus via an anterior retro-peritoneal approach,⁴ automated percutaneous nucleotomy,⁵ suction-excision of herniated lumbar discs, and chemonucleolysis and laser nuclear ablation.⁶⁻¹³

In the 1970s, Parviz Kambin and Hijikata started to use specifically designed cannulas for performing a percutaneous dorso-lateral nucleotomy, with a reported satisfactory outcome of 75% in their patients.¹⁴⁻¹⁶ The principle of mechanical nucleotomy was subsequently pursued by other investigators in the 1980s.^{17,18} Increased understanding of the endoscopic anatomy of the foraminal and extra-foraminal region,^{19,20} the description of radiographic landmarks of the working zone on the dorsolateral annulus by Parviz Kambin combined with the availability of smaller calibre rod-lens fibre-optics have permitted further lateralisation of the skin entry points.^{15,21,22} Specifically the later approaches had been pursued by Anthony Yeung,²³ Martin Knight,¹³ Sang Ho Lee,²¹ Thomas Hoogland and others.^{12,25-33} Over the last decade, all of them have performed some thousands of endoscopic spinal procedures using a very similar approach, but varying their specific methods and technologies.

The THESSYS™ Concept

For the removal of herniated inter-vertebral disc material, THESSYS (Transforaminal Endoscopic Spine System) utilises a special lateral, trans-foraminal

endoscopic approach. This represents a less traumatic approach for the patient than the typically used dorsal approach. With the use of dorsal laminectomy procedures for the removal of intra- and transforaminal disc fragments, extensive sacrificing of vital spinal stability structures can be required in order to reach the target point, often leading to immediate spinal fusion. In contrast, THESSYS allows access to every herniated disc fragment or protrusion except those located fully dorsally. The documented recurrence rate with the THESSYS method is very low.^{11,25,30-34} With this method, sequestered disc material is completely removed directly through the foramen, which is gradually widened in a step-wise fashion with specially designed reamers and accompanying instrumentation. The patient can be placed in both the prone position and the lateral position. He/she is awake during the entire operation, which is carried out under local anaesthesia. This allows communication with the patient during the entire procedure. The whole operation can be performed effectively in both a hospital and an out-patient surgery centre.

Operating Technique

Proper patient positioning and thorough planning of the approach to the herniated intervertebral disc via the skin entry point, as shown in the figures, is crucial in obtaining a good surgical outcome.

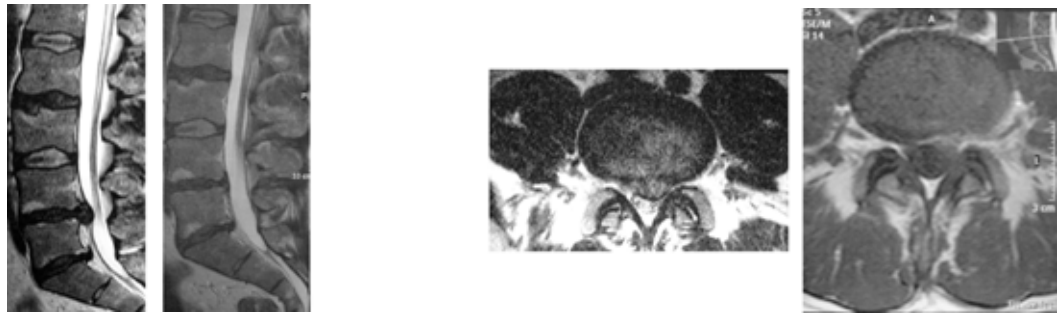
Confirmations of the exact position of an annular tear protrusion and/or sequestered intervertebral disc material can be obtained using the intra-operative discography.

With the combination of methodology and technology, the THESSYS total system makes access possible at all lumbar levels, including L5-S1. Any sequestered disc fragment or protrusions can be removed with the system immediately (see *Figure 1*).

The specific approach for herniated intervertebral discs using the method is through the intervertebral foramen, which most of the time is very narrow due to the disease. The affected nerve roots exit cranially



Florian Alfen is an orthopaedic surgeon in private practice in Würzburg, Germany. He also provides Endoscopic Transforaminal Nucleotomy treatments at the ARKADE Private Clinic, Niederschmalkalden, as well as at the HELIOS Private Clinic, Volkach, Germany. Previous to this he had been working at the ALPHA-Clinic Munich as an assistant medical director in the spine surgery section. A graduate of J-W-von Goethe University in 1993, Dr Alfen was a visiting doctor at Al Shatti Hospital, Oman, in 2003, and at Armed Forces Hospital, Oman, in 2005. Dr Alfen is a member of numerous societies and professional bodies, including the Orthopaedic Surgery Society, German Society for Spine Surgery, German Orthopaedists Association, and International Society for Medical Strengthening Therapy.

Figure 1: MRI Pre-operatively and Three Months Post-operatively

and are often encapsulated by fibrous tissue and/or bony structures. In order not to irritate any nerve close to the foramen and to ensure a safe access to the spinal canal, the caudal part (safety zone) of the foramen is widened millimetre by millimetre with specially designed reamers.

A stepwise, three-staged guide wire principle is used, inserting into the foramen, under X-ray control from the THESSYS manual instrumentation tray, which consists of a variety of guiding rods, guiding tubes, working cannulas and the previously mentioned crown reamers. The foramen is gradually widened by reaming bone material away. Because of this procedure, safe access to the spinal canal is enabled. Through this access channel and the specifically developed spinal foraminoscopes, which allow full endoscopic visualisation, the prolapsed disc material causing serious radicular symptoms can be removed using the specially developed forceps, graspers and punches.

Indication

The THESSYS operating method can be used in any minimally invasive surgical procedure on a herniated intervertebral disc. All sequestered disc material and protrusions of the lumbar spine (including level L5-S1,) can be removed with the complete system through the lateral transforaminal approach under local anaesthesia.

The use of the complete system is indicated in any radicular syndrome caused by a herniated intervertebral disc or major protrusion and long-term pain, in which conservative therapy failed to achieve sufficient improvement. A cauda equina syndrome represents an indication for immediate intervention. As with any herniated disc operation, a THESSYS operation also requires pre-operative magnetic resonance tomography (MRT) and regular X-ray imaging.

Statistics

Published international literature report a 75–85%

success rate for percutaneous nucleotomies performed by experienced spine specialists.^{15,35} Herniated intervertebral disc operations performed with the help of microscopic technologies, used in most centres, demonstrate an average success rate of 87%.^{19,35,36} In one-year and two-year follow-up studies, the application of the THESSYS method for the removal of sequestered intervertebral disc material, by referenced THESSYS users, has achieved a success rate of more than 90%.^{25,26,30–33,34} Overall, the early recurrence rate is under five per cent. In patients with a recurrent herniation, the success rate is more than 84%.^{25,26,30,31}

Statistics – Private practice Florian Maria Alfen (MD)

Evaluation

- 4/2004–5/2005, N=189
- Retrospective non-randomised clinical study
- Data compiled for single/multi-level endoscopic transforaminal nucleotomies (ETNs) from 4/2004–5/2005
- N=189 (48 female/141 male)
- Average age 50 years (range 24–79 years)

ETN – disc level (frequency of occurrence; N=189)

ETN – complication rate: 5.5% (N=147, FU 6w)

ETN – patient's satisfaction on the visual analog scale (VAS)

Conclusion

In our opinion, the ETN with THESSYS is a fully developed technique to remove lumbar spine disc herniations. The disadvantages are: a long learning curve, a two-dimensional view, the distinction of tissue and initial expense. The advantages are: local anaesthesia only, a reduced risk of infection, reduced risk of instability, less subsequent scars, open-door surgery and a shorter rehabilitation time. ■

References

1. Darzi A, Mackay S, "Recent advances in minimal access surgery", *BMJ* (2002);324: pp. 31–34.
2. Mixter WJ, Barr J S, "Rupture of the intervertebral disc with involvement of the spinal canal", *New England Journal Med* (1934); 211: pp. 205–210.
3. Dandy W E, "Loose cartilage from inter-vertebral disc simulating tumour of the spinal cord", *Arch Surg* (1929);19: pp. 660–672.
4. Hult L, "Retroperitoneal disc fenestration in low back pain and sciatica", *Acta Orthop Scand* (1956);20: pp. 342–348.
5. Courtheoux F, Theron J, "Automated percutaneous nucleotomy in the treatment of cervicobrachial neuralgia due to disc herniation", *J Neuroradiol* (1992);19: pp. 211–216.
6. Kambin P, Sampson S, "Posterolateral percutaneous suction-excision of herniated lumbar inter-vertebral discs; Report of interim results", *Clin Orthop* (1986); 207: pp. 37–43.
7. Hoogland T, Scheckenbach C, "Low-Dose Chemonucleolysis Combined with Percutaneous Nucleotomy in Herniated Cervical Discs", *Journal of Spinal Disorders* (1995); 8(3): pp. 228–232.
8. Schubert M, Hoogland T, "The endoscopic transforaminal nucleotomy in combination of a low-dose chemonucleolysis: Results of a prospective study with 2-year follow-up", *Program Abstract at the 18th Annual Meeting of the International Intradiscal Therapy Society* (2005); San Diego.
9. Chiu J, Clifford T, "Micro-decompressive percutaneous discectomy: Spinal discectomy with new laser thermolysis for non extruded herniated nucleus pulposus", *Surg Technol Int* (1999);3: pp. 343–351.
10. Choy D S J, Case R E, Fielding W, "Percutaneous laser nucleolysis of lumbar discs", *New England Journal Med* (1987);317: pp. 770–771.
11. Gastambide D, "Endoscopic posterolateral foraminotomy with instruments or laser for lateral lumbar stenosis", *Program Abstract at the 17th Annual Meeting of the International Intra-discal Therapy Society* (2004) Munich.
12. Hellinger J, "Technical aspects of the percutaneous cervical and lumbar laser-disc-decompression and laser-nucleotomy", *Neurol Res* (1999);21: pp. 99–102.
13. Knight M et al (eds), "Endoscopic Laser Foraminoplasty. A two year follow-up of a prospective study on 200 consecutive patients", *Lumbar Spinal Stenosis*, Lippincott Williams and Wilkins, Ed. Gunzberg and Spalski (1999): pp. 244–254.
14. Kambin P, "Arthroscopic microdiscectomy: lumbar and thoracic", *Spine Care St. Louis, Mosby White A H, Schoffermann J A (eds)(1955);2: pp. 1002–1016.*
15. Kambin P, Gellman H, "Percutaneous lateral discectomy of lumbar spine, a preliminary report", *Clin Orthop* (1983);174: pp. 127–132.
16. Hijikata S, Yamagishi M, Nakayama T, et al, "Percutaneous nucleotomy. A new treatment method for lumbar disc herniation", *J Toden Hosp* (1975);5: pp. 5–13.
17. Onik G, Helms C, Ginsburg L, et al, "Percutaneous lumbar discectomy using a new aspiration probe", *AJR* (1985);144: pp. 1137–1140.
18. Schreiber A, Suezawa Y, Leu H J, "Does percutaneous nucleotomy with discoscopy replace conventional discectomy? Eight years of experience and results in treatment of herniated lumbar disc", *Clin Orthop* (1989);238: pp. 35–42.
19. Hermantin F, Peters T, Quartararo L, "A prospective, randomized study comparing the results of open discectomy with those of video-assisted arthroscopic microdiscectomy" *J Bone Joint Surg (A)*(1999);81: pp. 958–965.
20. Kambin P, "Arthroscopic techniques for spinal surgery", *McGinty J B, Caspari R B, Jackson R W, et al., (eds) Operative Arthroscopy Philadelphia, Lippincott-Raven* (1996);2: pp.1207–1235
21. Kambin P, "Posterolateral percutaneous lumbar discectomy and decompression" *Arthroscopic Microdiscectomy, Minimal Intervention in Spinal Surgery, Kambin P,(ed) Baltimore, Urban & Schwarzenberg*(1991): pp. 67–121.
22. Kambin P, Casey K, O'Brien E, et al., "Trans-foraminal arthroscopic decompression of lateral recess stenosis.", *J Neurosurg* (1996); 84: pp. 462–467.
23. Yeung A, Tsou P, "Posterolateral Endoscopic Excision for Lumbar Disc Herniation", *Spine* (2001); 27(7): pp. 722–731.
24. Ahn Y, Lee SH, Park W M, et al., "Posterolateral percutaneous endoscopic lumbar foraminotomy for L5-S1 foraminal or lateral exit zone stenosis", *J Neurosurg* (2003);99(3): pp. 320–323.
25. Hoogland T, "Transforaminal endoscopic discectomy with foraminoplasty for lumbar disc herniation", *Surg Techn in Orthopaedics and Traumatology* (2003);40: pp. 55–120.
26. Hoogland T, "Percutaneous nucleotomy of thoracic discs", *Program Abstract at the 17th Annual Meeting of the International Intra-discal Therapy Society* (2004); Munich.
27. Hoogland T, Godon T, Wagner C, "Die endoskopische transforaminale Diskoplastik bei überwiegend lumbalen Rückenschmerzen", *Program Abstract at the 52. Jahrestagung der Vereinigung Süddeutscher Orthoäden*(2004);Baden-Baden.
28. Alfén F M , "Endoscopic Transforaminal Nucleotomy (ETN)", *Program Abstract at the 3rd Dubai Spine Conference* (2005); Dubai.

29. Gibson A, "Surgery for lumbar disc prolapse: Evidence from the 2004 Cochrane review", Program Abstract at the 17th Annual Meeting of the International Intradiscal Therapy Society (2004) Munich.
30. Ipreburg M, "Percutaneous Transforaminal Endoscopic Discectomy; the learning curve to achieve a more than 90% success rate", Program Abstract at the 19th Annual Meeting of the International Intradiscal Therapy Society (2006);Phoenix.
31. Krzok G, "Early results after posterolateral endoscopic discectomy with thermal annuloplasty", Program Abstract at the 17th Annual Meeting of the International Intradiscal Therapy Society (2004) Munich.
32. Levinkopf M, Caspi I et al., "Posterolateral Endoscopic Discectomy", Program Abstract at the 18th Annual Meeting of the International Intra-discal Therapy Society (2005);San Diego.
33. Schubert M, Hoogland T, "Endoscopic Transforaminal Nucleotomy with Foraminoplasty for Lumbar Disc Herniation", Oper Orthop Traumatol (2005);17: pp. 641–661.
34. Alfén FM, Lauerbach B, "Technique and Results of Endoscopic Transforaminal Nucleotomy (ETN)", Program Abstract at the 13th Congress of the International Musculoskeletal Laser Society (2006);Barcelona.
35. Leu HJ, Schreiber A, "Percutaneous fusion of the lumbar spine, a promising technique", Spine State Art Rev (1992);6: pp. 593–604.
36. Lüthmann D, Burkhardt-Hammer T, Borowski C, et al., "Minimally invasive surgical procedures for the treatment of lumbar disc herniation", DIMDI, German Agency for Health Technology Assessment at the German Institute of Medical Documentation and Information (2005): DAHTA@DIMDI.
37. Mayer H, Brock M, "Percutaneous endoscopic discectomy: Surgical technique and preliminary results compared to microsurgical discectomy", J Neurosurg (1993);78: pp. 216–225.
38. Casey K F, Chang M K, O'Brien E D, et al., "Arthroscopic microdiscectomy, comparison of preoperative and postoperative imaging studies", Arthroscopy (1997);13: pp. 438–445.
39. Hochschulter S H, "Posterior lateral arthroscopic microdiscectomy", Semin Orthop (1991);6: pp. 113–114.
40. Kambin P, O'Brien E, Zhou L, "Arthroscopic microdiscectomy and fragmentectomy", Clin Orthop (1998);347: pp. 150–167.
41. LaRocca H, McNab I, "The laminectomy membrane. Studies in its evolution, characteristics, effects and prophylaxis in dogs", J Bone Surg (Br)(1974); 56: pp. 545–550.
42. Lowery GL, Bernauer D, Casper D, et al., "Endoscopic posterolateral lumbar fusion and pedicle screw fixation: Early results from a multi-center prospective study", Program Abstract at the World Spine II Meeting(2003);Chicago.
43. Mathews H, Long B, "Minimally Invasive Techniques for the Treatment of Intervertebral Disc Herniation", Journal of the American Academy of Orthopaedic Surgeons (2002);10(2): pp. 80–85.
44. McAfee P C, "Thoracolumbar spinal corpectomy", Atlas of Endoscopic Spine Surgery, St. Louis, Regan J J, McAfee P C, Mark M J (eds) Quality Medical Publishing (1995): pp. 189–197.
45. Mochida J, Nishimura K, Okuma M, et al., "Percutaneous Nucleotomy in Elite Athletes", In: Journal of Spinal Disorders (2001);14(2): pp. 159–164.
46. Osman S, Nibu K, Panjabi M, et al., "Transforaminal and Posterior Decompressions of the Lumbar Spine" Spine (1997);22: pp. 1690–1693.
47. Parke W W, "Clinical anatomy of the lower lumbar spine", Arthroscopic Microdiscectomy, Minimal Intervention in Spinal Surgery, Baltimore, Kambin P (ed) Urban & Schwarzenberg (1991): pp. 11–29.
48. Schaffer J L, Kambin P, "Percutaneous posterolateral lumbar discectomy and decompression with a 6.9 millimeter cannula. Analysis of operative failures and complications", J Bone Joint Surg (Am) (1991);73: pp. 822–831.
49. Scheckenbach C, Hoogland T, "Endoskopische transforaminale Diskektomie (EDT) – Ergebnisse nach 2 Jahren", Orthopädische Praxis (1999);35(2): pp. 104–105.